DAWN MEATS

Organ	MHS Condition	Description	Common Causes
HEAD	Abscess	Pockets of infection within the head tissue.	Can be caused by sharp, or pointed material in feed/forage which cause small puncture wounds which can lead to infection.
	Actinomycosis	Commonly known as 'lumpy jaw'.	As above - usually caused when the gum/tissue lining becomes damaged which allows the bacteria to penetrate and cause infection.
LIVER	Abscess	Infection within the liver.	Can be caused by the consumption of high quantities of concentrate feeds.
	Fascioliasis Live	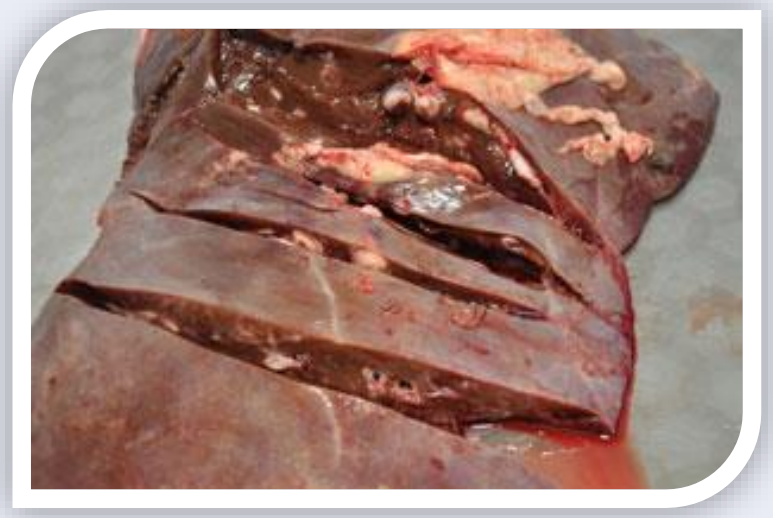 *Figure 1: Damage caused by Liver Fluke* Live Liver fluke - a parasite which causes damage by migrating from the stomach through the liver to the bile ducts (Figures 1 and 2)	*Figure 2: Live liver fluke within a bovine liver.* Ineffective/no treatment. Resistance to drug used. High risk pasture – wet/ boggy areas.
	Fascioliasis Calcified/Historic	Past evidence of liver fluke damage - although the fluke themselves are not present.	It is likely that treatment has been successful following previous infestation.
	Telangiectasis	Also known as 'plum pudding liver' - lesions within the liver formed by the dilation of groups of blood vessels.	Cause largely unknown, thought to be related to hormonal changes so occurs more frequently in older cows.
	Hydatidosis	Cysts within the liver, commonly 5 to 10cm in diameter which contain fluid.	Hydatid cysts are can be caused by the larval stages of the dog tapeworm Echinococcus granulosus.

DAWN MEATS

Organ			
HEART	Pericarditis	Inflammation of the fluid sac which surrounds the heart	Known to have multiple causes, although it is often caused by trauma e.g. regurgitated pieces of wire.
KIDNEYS	Nephritis/Nephrosis	Inflammation of one or both kidneys.	Can have multiple causes.
	Cystic	Fluid filled sacs present.	Multiple causes.
LUNGS	Pneumonia	Inflammation of the lung tissue itself.	Can be caused by viruses, bacteria, fungi and parasites such as lungworm.
	Pleurisy	Inflammation of the pleura - a membrane which covers the lungs, heart and walls of the chest cavity.	Tends to be a complication following pneumonia.
TONGUE	Actinobacillosis	Commonly known as 'wooden tongue.'	Rough herbage and foreign objects within feed can contribute to the frequency of this condition. Can cause reduced feed intake.
OTHER GENERIC TERMS THAT CAN AFFECT ANY BODY PART	Xanthosis	Causes dark brown pigmentation of the meat	Most commonly affects the heart, tongue and cheek muscles.
	Peritonitis	Inflammation/infection in the membrane which lines the abdominal cavity.	Can have multiple potential causes, including infection.
	Cysticercus bovis (C. Bovis)	Cysts formed by the human tapeworm Taenia Saginata in the muscles of cattle which are the intermediate host.	Cattle become infected and develop cysts when they consume human faecal material - If viable cysts are consumed by humans e.g. in undercooked beef the lifecycle is completed. The only way to prevent transmission to humans is to deep freeze the meat at a temperature not exceeding -7°C for 3 weeks.

The definitions used in this glossary are general and only meant as a guide.
Should you require further information regarding these conditions and the affect they may have on your production system please contact your veterinary surgeon.